

Targeted alpha therapy for thyroid cancer: Radiation-induced toxicity of [²¹¹At]NaAt in mice[†]

Y. Liu,^{*2} T. Watabe,^{*2,*3} K. Kaneda-Nakashima,^{*3,*4} K. Ooe,^{*1,*2} Y. Shirakami,^{*3} A. Toyoshima,^{*1,*3}
E. Shimosegawa,^{*2} T. Nakano,^{*3,*5} A. Shinohara,^{*3,*4} and J. Hatazawa^{*3,*5}

Radioactive iodine (RAI) therapy is used for the treatment of patients with differentiated thyroid cancer.^{1,2)} However, a percentage of patients shows insufficient ¹³¹I accumulation³⁾ or low therapeutic effect even with enough ¹³¹I accumulation, and some patients suffer from recurrence or metastases and become RAI-refractory during follow-up.^{4,5)} For these patients, a more effective treatment is required.

Astatine (²¹¹At) is a halogen with chemical properties similar to those of iodine, but it emits alpha particles, and we have found that the radiochemical purity of astatide dramatically improves upon treatment with 1% ascorbic acid. Consequently, the uptake of ²¹¹At increases in the thyroid gland and thyroid cancer cells.⁷⁾ In this study, we evaluated the radiation-induced toxicity of different doses of ²¹¹At-NaAt solution at different time points to estimate its time-dependent toxicity.

Methods

The biodistribution of ²¹¹At-NaAt was measured in normal ICR mice ($n = 12$) and the absorbed doses in major organs were calculated.

Groups of ICR mice ($n = 60$) were injected with 0.1 MBq or 1 MBq of ²¹¹At-NaAt using saline as the control group ($n = 30$). Their body weight and food intake were followed up for 60 days. The blood cell count and serum level of biochemical parameters were measured 3, 7, 15, 29, and 60 days after injection. Histological analyses of major organs with hematoxylin and eosin staining were performed.

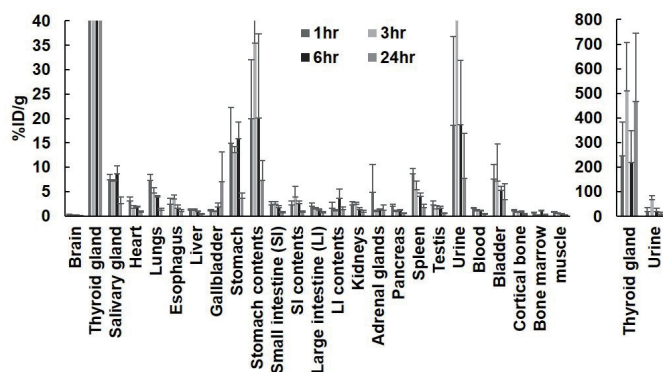


Fig. 1. %ID/g of main organs in normal ICR mice administered with ²¹¹At-NaAt solution.

[†] Condensed from the article in *Transl Oncol.* **13**, 4 100757 (2020)

*1 RIKEN Nishina Center

*2 Graduate School of Medicine, Osaka University

*3 Institute for Radiation Sciences, Osaka University

*4 Graduate School of Science, Osaka University

*5 Research Center for Nuclear Physics, Osaka University

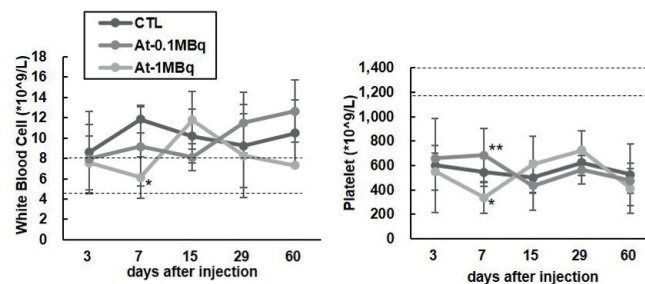


Fig. 2. Evaluation of hematological toxicity in the control, 0.1 MBq, and 1 MBq groups.

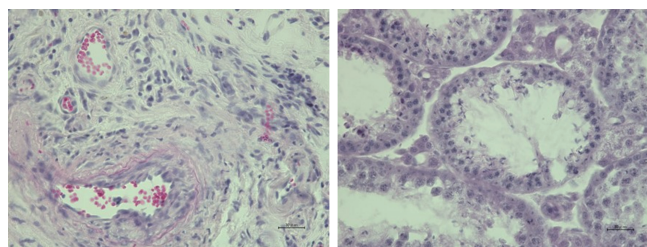


Fig. 3. Histological changes in the thyroid gland (left) and testis (right) evaluated by HE staining in the 1 MBq group on day 29.

Results

Figure 1 revealed a high-absorbed dose in the thyroid gland, stomach, bladder, heart, lungs, spleen, kidneys, and testes. The 0.1 MBq group showed no abnormalities. The 1 MBq group showed decreased body weight and food intake. Figure 2 showed that hematological toxicity was mild and transient. The total cholesterol, albumin, and total protein increased with no signs of recovery, which can be attributed to hypothyroidism. Figure 3 showed atrophy and fibrosis in the thyroid gland and a transient hypospermatogenesis was found in the testis of one mouse on day 29.

Conclusion

High-dose administration of ²¹¹At-NaAt showed transient toxicity in the white blood cells and testis without severe hematological or renal toxicity, suggesting its tolerable safety as targeted alpha-therapy for differentiated thyroid cancer in the 1 MBq group.

References

- 1) H. R. Maxon *et al.*, *J. Nucl. Med.* **33**, 1132 (1992).
- 2) Y. K. Maheshwari *et al.*, *Cancer.* **47**, 664 (1981).
- 3) L. M. Cobb *et al.*, *Radiother. Oncol.* **13**, 203 (1988).
- 4) Y. Jin *et al.*, *Crit. Rev. Oncol. Hematol.* **125**, 111 (2018).
- 5) M. Schlumberger *et al.*, *Lancet Diabetes Endocrinol.* **2**, 356 (2014).
- 6) M. R. Zalutsky *et al.*, *Curr. Pharm. Des.* **6**, 1433 (2000).
- 7) T. Watabe *et al.*, *J. Nucl. Med.* **60**, 1301 (2019).